



Topical Update – The Hong Kong College of Pathologists

The Hong Kong College of Pathologists, Incorporated in Hong Kong with Limited Liability

Volume 7, Issue 2

July 2012

Editorial note:

Many of us who have tried operating an electron microscope would share the frustration of spending the whole afternoon sitting in the darkroom searching for the pathology. While reading up from an atlas or awaiting another colleague to confirm the ultrastructural finding, the section in the field of interest was destroyed by the electron beam. It is not feasible to install an electron microscope in every laboratory because of the high cost as well as the required space and technical expertise. In this topical update, we would like to share the local experience of the use of virtual electron microscopy (EM) in routine renal biopsy service, an invention which has revolutionized and may re-popularize EM practice. We welcome any feedback or suggestion. Please direct them to Dr Patrick Lau Pak Lun (email: lau_pak_lun@yahoo.com) for Education Committee, The Hong Kong College of Pathologists. Opinions expressed are those of the authors or named individuals, and are not necessarily those of the Hong Kong College of Pathologists.

Virtual Electron Microscopy – update after one year of routine use



Dr. King Chung Lee

Consultant Pathologist, St. Paul's Hospital
Honorary Consultant, Queen Elizabeth Hospital

Background

Virtual microscopy using whole slide scanning has become increasingly popular in quality assurance program, teaching of pathologists and undergraduates and reproducibility studies¹⁻². This concept was first extended to electron microscope

(EM) about a year ago³. This is made possible by two discoveries. Firstly, a free software component capable of stitching sequential pictures into a virtual slide that can be read by another free software. Secondly, an EM function capable of capturing up to 500 images covering a specified area automatically. Because of the simplicity,

acceptable degree of user intervention during the process and unsurpassed advantages over the conventional method, it was quickly adopted in routine renal biopsy diagnostic EM service and become the only routine service virtual microscopy system in Hong Kong. For those who are interested, you can download a sample from <http://kvisit.com/SsKKqAQ> and view it by Aperio ImageScope software, which was available for free download from the Aperio website, <http://www.aperio.com/download-imagescope-viewer.asp>.

Summary of implementation

In the last year, over 400 renal biopsy cases were handled in our EM laboratory and over 1000 virtual ultrathin sections were generated (average 2.7 sections per case). The average EM time used in capturing is about 50 minutes per section. The average computing time is 40 minutes per section. The virtual ultrathin sections were either directly interpreted by Pathologists or screened and annotated by our EM technologist before passing to Pathologists.

The virtual ultrathin sections have a much higher contrast than the image on fluorescent screen of electron microscope. The difference is especially dramatic in “low power” (x1100 using a 5:4 aspect ratio 19” display), allowing a diagnostically useful overview. The experience in reading light microscopy can be directly applied to this “low power” and areas of interest can be located and zoomed in for ultrastructural assessment. Another advantage is much faster navigation both to adjacent fields and distant fields in the section. It also allows keeping track of the area under view with respect to the whole section, an important feature not possible at all when viewing directly under EM. Viewing of computer monitor under comfortable ambient light is definitely more appealing than the conventional work environment of an EM room.

As a result both technical and medical staff welcomed this innovation and transition from the conventional method was very smooth.

After a year of routine use, we noticed improved learning curve in interpretation of ultrathin section both in technical and medical staff. Assessment of abundance and distribution of lesion is more reliable. Moreover, because of the much improved contrast, even unstained sections can be used to generate a virtual slide of acceptable quality, with slightly increased noise only. Hence, turn around time for EM processing is reduced.

Basement membrane thickness assessment using virtual ultrathin section

All the currently described methods on basement membrane thickness assessment involved measurements performed on photos or digital images taken from selected areas in a glomerulus using different criteria⁴⁻⁵. With whole glomerulus scanning, we can perform systematic measurement covering the entire glomerulus. One of the possible methods is to draw vertical lines 20 micron apart (using the browser software, of course) through the virtual slide. In general, around 10 lines can be drawn, depending on the size of the glomerulus. Wherever the lines touch luminal side of glomerular capillary, a measurement is performed. The measurement is done between the endothelial cell basement membrane and the visceral epithelial cell basement membrane. In order to avoid areas of tangential section, only regions with the basement membrane forming a solid sharp line or with the endothelial cell fenestration show up as gaps (as opposed to sieve) in flattened endothelial cell cytoplasm should be used for measurement. Moreover, areas of subendothelial widening and sudden scalloping should be avoided. Obviously, we should not make measurement across adjacent picture tiles as the stitching is not perfect. Hence, not all the regions where these lines intercept with endothelial cell basement membrane can be measured. To increase the number of measurements, a suitable region within a certain distance (say 1 micron) from the line can also be used for measurement. In general, 20 to 50 measurements can be taken from each glomerulus. Since during the measuring process, the tangentially cut areas are avoided, we can use arithmetic mean instead of harmonic mean for the

calculation. In the limited cases (n=9) that I have done measurements using the above described method and measurements including the tangential region followed by harmonic mean, there is no demonstrable difference (no statistical difference, $p = 0.18$, unpublished data).

Challenges ahead

The current version can only be considered partial slide scanning as we capture an area of 200 x 200 micron at a time. While we can capture a larger area using a lower magnification, the resulted virtual slide will not be diagnostically useful. Therefore, this version cannot be applied to EM study of tumor, muscle or nerve where well defined area of interest (the glomerulus in renal biopsy cases) is lacking. In order to allow whole ultrathin section scanning, the speed of capturing needs to be increased by 10 to 15 times. The capturing process has two components: exposure and movement of stage. Theoretically, we can reduce the exposure time by 10 fold using lanthanum hexaboride (LaB₆) instead of tungsten filament. However, this contributed little to the overall speed as stage movement takes up 85% of total time. Therefore solicit participation from EM manufacturer is essential to meet this challenge.

Due to aberration in the electro-magnetic lenses and uneven expansion of the ultrathin section when exposed to the electron beam, the virtual slide produced by simple stitching is not perfect⁶. Moreover, picture capture function in the EM machine apply a simple auto-level function producing pictures of different brightness depending on the electron density of the structures covered by the image. In general, the image is underexposed when it covers empty regions of the section or holes and overexposed when it covers grid bar or stain deposits. There are potential solutions published in the literature already⁶ but implementation still needs input from experts in this field. Nevertheless, while these imperfections generate visually less appealing slide, they does not affect the diagnostic value.

For some unknown reasons, the ImageScope software occasionally stopped responding to

navigation commands. It is important to wait and it will respond normally after a while (usually less than a minute). I find resetting the cache memory (tools → advanced. menu item) helps a bit.

In summary, there are a lot of improvements possible if input from experts in applied mathematics, programming and mechanics is available. Nevertheless, this primitive system already finds a very special niche in ultrastructural renal biopsy interpretation.

Reference

1. Li L, Dangott BJ, Parwani AV. Development and use of a genitourinary pathology digital teaching set for trainee education. *J Pathol Inform.* 2010;May 26:1. pii: 2.
2. Bruch LA, De Young BR, Kreiter CD, Haugen TH, Leaven TC, Dee FR. Competency assessment of residents in surgical pathology using virtual microscopy. *Hum Pathol.* 2009;40:1122-8.
3. Lee KC, Mak LS. Virtual electron microscopy: a simple implementation creating a new paradigm in ultrastructural examination. *Int J Surg Pathol.* 2011 19:5: 570-5.
4. Dische F. Measurement of glomerular basement membrane thickness and its application to the diagnosis of thin-membrane nephropathy. *Arch Pathol Lab Med* 1992; 116: 43-49
5. McLay AL, Jackson R, Meyboom F, Boulton Jones JM. Glomerular basement membrane thinning in adults: clinicopathological correlations of a new diagnostic approach. *Nephrol Dial Transplant* 1992; 7: 191-199
6. Kaynig V, Fischer B, Müller E, Buhmann JM. Fully automatic stitching and distortion correction of transmission electron microscope images. *J Struct Biol.* 2010 Aug;171:163-73.

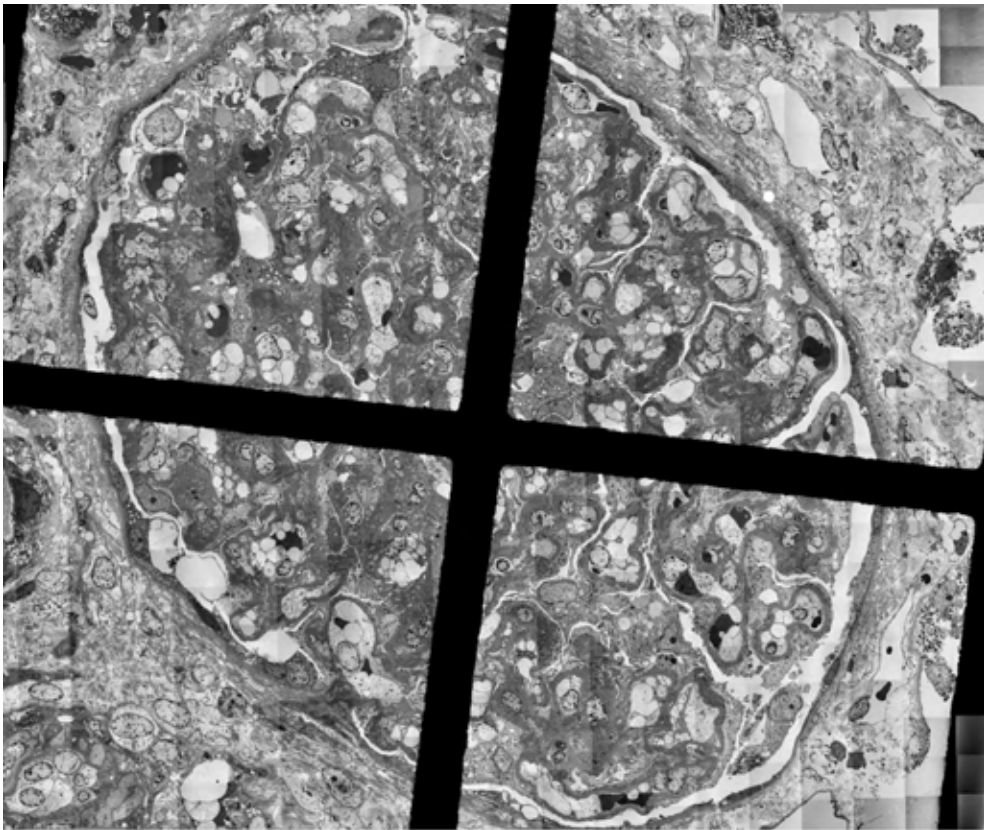


Figure 1 – Low power view showing thickening of glomerular basement membrane with subepithelial deposits

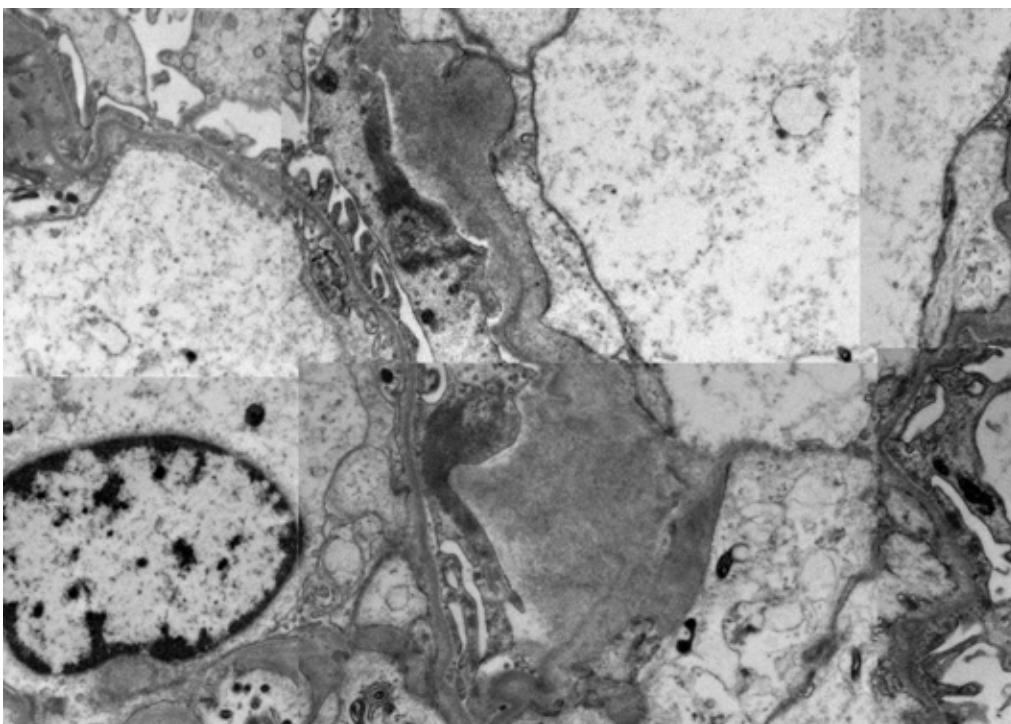


Figure 2 – High power view showing widening of basement membrane by fibrillary material, consistent with amyloid.

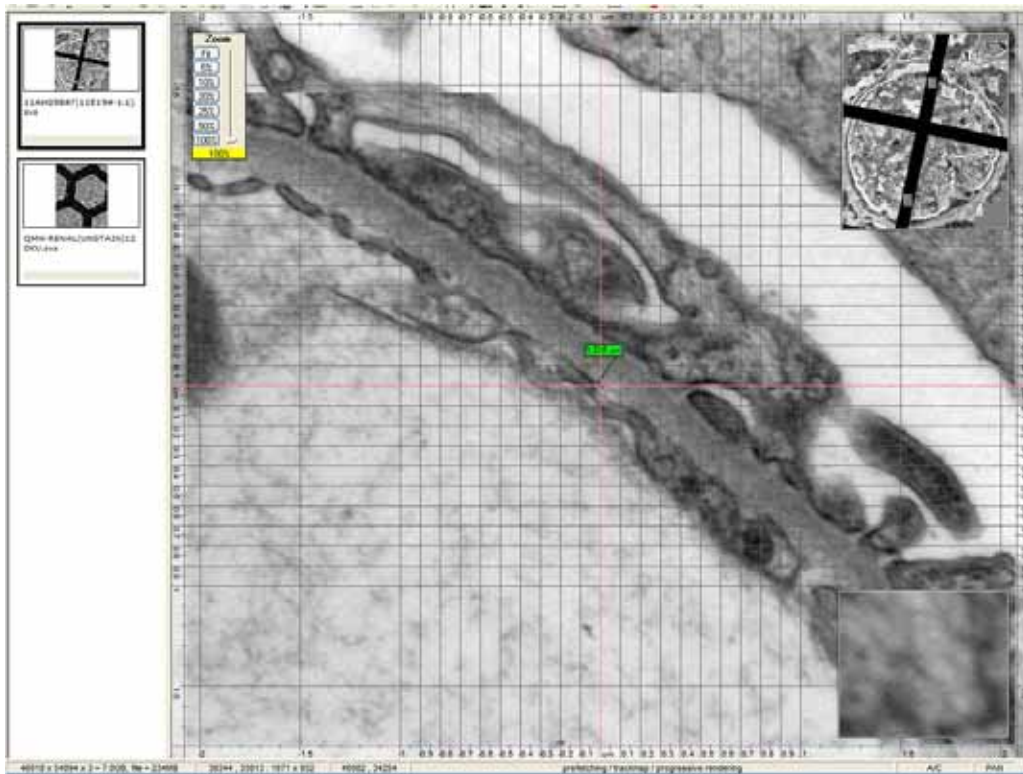


Figure 3 – Perpendicularly cut area with fenestrations showing up as gaps. Basement membrane measurements can be performed here.




Figure 4 – Tangentially cut area with fenestrations showing up as sieves. Basement membrane measurements should be avoided here.