

# A rare case of constitutional mismatch repair deficiency syndrome in a 2-year-old girl with medulloblastoma and signs of neurofibromatosis type 1

WONG WF

Department of Clinical Pathology, Tuen Mun Hospital, Hong Kong

## Introduction

Constitutional mismatch repair deficiency (CMMRD) syndrome is an autosomal recessive disorder characterized by biallelic germline inactivation of one of the DNA mismatch repair (MMR) genes. Patients with CMMRD syndrome commonly have childhood-onset malignancies, mainly haematological malignancies, brain tumour and Lynch syndrome-associated carcinomas. Inactivation of different MMR genes is reported to have different phenotypes.

Medulloblastoma is the most common CNS embryonal tumour and the most common malignant tumour of childhood. Although not the most common brain tumour in CMMRD syndrome, it was reported in some cases. I would like to report a case of cerebellar anaplastic medulloblastoma (group 3) in a 2-year-old girl. Both the tumour tissue and background normal tissue were revealed to have loss of MSH6 immunohistochemical staining. Next-generation sequencing performed on patient's blood revealed two pathogenic variants in MSH6 (one variant inherited from father and the other from mother), consistent with the diagnosis of CMMRD syndrome.

The genetic and clinical implications on the patient and her family will be discussed. The incidence of malignancies and the phenotypes of various mutations in CMMRD syndrome will be reviewed. The diagnostic clues of this syndrome will also be discussed.

## Case Report

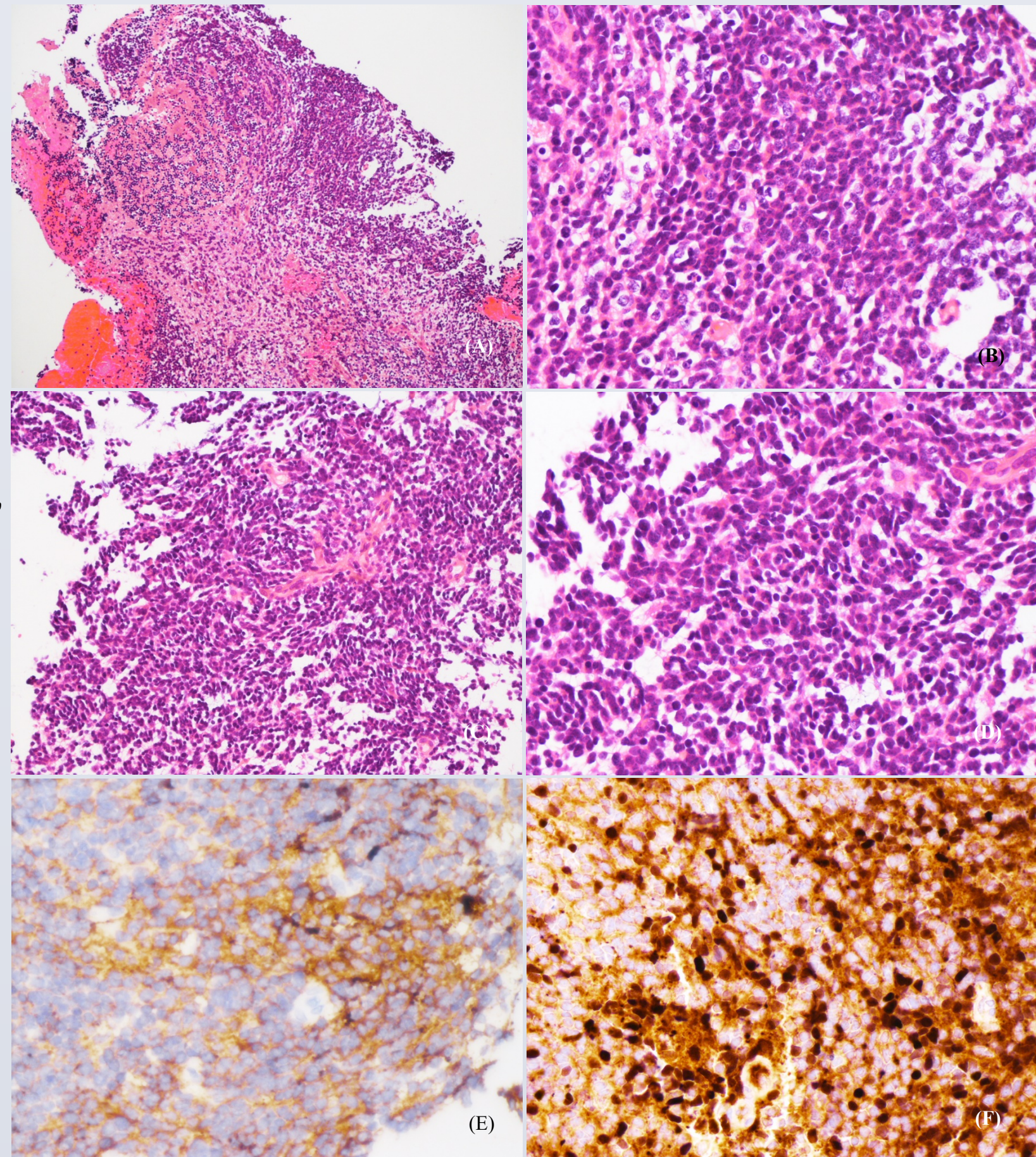
A 28-month-old girl was presented with speech delay and suspected hearing impairment in October 2019. She was a full term baby with follow up at Paediatric outpatient clinic for ridging coronal suture. Family history included laryngeal cancer in maternal grandfather, oesophageal cancer in brother of maternal grandfather and cancer of corpus uteri in paternal grandmother. Her 7-year-old elder brother enjoyed good past health.

In view of multiple café au lait spots, acoustic neuroma was suspected. MRI brain showed an 8 mm midline enhancing lesion at the cerebellar vermis, which caused bulging contour of right side of fourth ventricle. No significant perifocal oedema, mass effect or hydrocephalus was present. No drop metastasis was detected by MRI spine.

Gross total excision of the tumour was performed in November 2019. Histology of the tumor showed fragments of highly cellular and reticulin-poor tumour tissue and bland-looking cerebellar tissue. The tumour cells are arranged in sheets, and possess hyperchromatic nuclei and indistinct cytoplasm. Nuclear moulding was readily identified. Abundant mitosis and apoptosis were present. Immunohistochemically, the tumor cells were focally positive for Synaptophysin and S100, while negative for p53, GFAP, EMA and smooth muscle Actin. INI1 staining was preserved. Ki-67 proliferative index was 50%.

Fluorescent in situ hybridization for c-myc and MYCN amplifications were both negative.

A diagnosis of cerebellar anaplastic medulloblastoma was made. By NanoString, this tumour was classified as group 3.



(A) Tumour tissue with adjacent cerebellar tissue (100X). (B) Higher power view of (A) (400X). (C) Another view of tumour tissue (100X). (D) Higher power view of (C) (400X). (E) Focal positivity for Synaptophysin IHC (400X). (F) Focal positivity for S100 IHC (400X)

## Progress

In view of multiple café au lait spots, CMMRD syndrome and neurofibromatosis type 1 were suspected. Further immunohistochemical staining showed complete loss of MSH6, both in tumour cells and background normal cerebellum. Staining for other MMR proteins (MLH1, PMS2 and MSH2) were preserved. Next-generation sequencing of NF1, MLH1, MSH2, MSH6, PMS2, BRCA2, PALB2 was then performed on the peripheral blood of the patient. Two pathogenic variants of MSH6 gene, each inherited from one of the patents, were detected as follows,

- Nonsense variant MSH6 c.718C>T p.(Arg240\*) (from father (33 years old))
- Small frameshift duplication MSH6 c.3934\_3937dup p.(Ile1313Serfs\*7) (from mother (32 years old))

The genetic findings are consistent with the diagnosis of constitutional mismatch repair deficiency (CMMRD) syndrome.

The patient was given a course of chemotherapy followed by three tandem autologous peripheral stem cell transplant. The patient was well until 11 months after the operation when she presented with repeated vomiting. MRI brain and spine showed local recurrence at the fourth ventricle, extensive leptomeningeal metastases involving the cerebellum, pons, optic nerves and the entirety of the spinal cord, and nodular drop metastases involving the right inferior frontal lobe, bilateral frontal horns and at the tip of the thecal sac. Mild interval increase in ventricular dilatation was also detected. Checkpoint inhibitors (Nivolumab and Ipilimumab) were started. Ventriculoperitoneal shunt was performed in view of further clinical and radiological deterioration of hydrocephalus. However, her condition further deteriorated and she eventually succumbed at 12 months after the operation.

## Discussion

### Implication of CMMRD syndrome on our patient and her family

CMMRD syndrome is an autosomal recessive disorder characterized by biallelic germline inactivation of one of the MMR genes (MLH1, MSH2, MSH6 and PMS2). In contrast, in Lynch syndrome (also known as hereditary non-polyposis colorectal cancer) there is monoallelic germline inactivation of one of the MMR genes, with increased adulthood risks of malignancies of colorectum, endometrium, ovary, etc. Patients with CMMRD syndrome commonly have childhood-onset malignancies, mainly haematological malignancies, brain tumour, Lynch syndrome-associated carcinomas and other malignancies.<sup>1</sup>

Our patient was confirmed to have inherited one pathogenic variant of MSH6 gene from each of the parents. This implies a genetic diagnosis of Lynch syndrome in both parents. Regular surveillance for malignancies, e.g. colonoscopy for colorectal carcinoma, endometrial biopsy for endometrial carcinoma, urine cytology and urinary system ultrasonography for urothelial carcinoma, are indicated and should be performed according to institutional guidelines.

Our patient's elder brother is also at risk of CMMRD syndrome and Lynch syndrome, with 25% chance for the former and 50% chance for the latter. Similar risks also apply for future siblings. Parents should be informed of the availability of prenatal genetic testing, and their wish as to whether to test be respected.

### Incidence of malignancies in CMMRD syndrome

The European Consortium 'Care for CMMRD' reported in 2015 a series of 139 patients with CMMRD syndrome.<sup>2</sup> Two hundred and twenty-three malignancies were identified, including 48 haematological malignancies (most commonly non-Hodgkin's lymphoma), 81 malignant central nervous system tumours, 88 Lynch syndrome-associated malignancies (most commonly colorectal and small intestinal adenocarcinomas), and 8 other malignancies (e.g. neuroblastoma and nephroblastoma). Among the 81 malignant central nervous system tumours, medulloblastoma was the third most common (n=7), following high grade glioma (n=58) and supratentorial primitive neuroectodermal tumour (n=8).

This finding on distribution of central nervous system tumour type concurred with another case series by Lavoine N et al in 2014.<sup>1</sup> Sixteen seven malignancies were identified among 31 patients with CMMRD syndrome. Among these, 22 were brain or spinal cord tumours, with 20 being glioblastoma and other glial tumours, and the remaining 2 cases being medulloblastomas.

### Phenotypes of CMMRD syndrome

The European Consortium 'Care for CMMRD' also reported differences in the prevalence of tumour groups among CMMRD patients with different mutations.<sup>2</sup> Brain tumours were more prevalent in PMS2 mutation carriers and MSH6 mutation carriers, and less prevalent in MLH1/MSH2 mutations. 60% of MSH6 mutation carriers developed a brain tumour as first malignancy, in contrast to 50% in PMS2 mutation carriers and 30% in MLH1/MSH2 mutation carriers.

### Diagnosing CMMRD syndrome – Recent advances

Various algorithms/systems were proposed to select individuals to undergo further testing for suspected CMMRD syndrome. According to the algorithm by Carol A. Durno et al<sup>3</sup>, childhood brain tumour (medulloblastoma as in our case) with neurofibromatosis type 1 features (multiple café au lait spots as in our case) should have immunohistochemistry for MMR proteins on tumour sample. As MSH6 immunohistochemical staining was lost in both tumour and normal tissue of our case, CMMRD syndrome was suspected and eventually confirmed by next-generation sequencing.

The European Consortium 'Care for CMMRD' proposed a scoring system in which an individual with a score of 3 points or above should be suspected for CMMRD syndrome<sup>2</sup>. Under this system, our patient scored 3 points based on malignancy before 18 years old and clinical signs of neurofibromatosis type 1. Other criteria include certain tumour types, family history of Lynch syndrome or Lynch syndrome-associated carcinoma, consanguineous parents, etc. Analysis of microsatellite instability and/or immunohistochemistry for MMR proteins should be performed for suspected cases of CMMRD syndrome.

These algorithms/systems are expected to enhance the detection of CMMRD syndrome.

## Conclusion

I report a rare case of constitutional mismatch repair deficiency syndrome in a 2-year-old girl with medulloblastoma and signs of neurofibromatosis type 1. A timely diagnosis of CMMRD syndrome is important as patients are prone to second malignancy. Parents and siblings may also benefit from genetic screening, which allows genetic diagnosis of Lynch syndrome/CMMRD syndrome before development of malignancy. A high index of clinical suspicion is crucial for diagnosing CMMRD syndrome.

## Acknowledgements

I would like to express my gratitude to Professor HK NG, Department of Anatomical and Cellular Pathology, Faculty of Medicine, The Chinese University of Hong Kong, and Doctor Amanda KAN, Doctor Tsz Wai YAU and Doctor Yuet Ping Liz YUEN, Department of Pathology, Hong Kong Children Hospital, for their expert opinion on this case.

## Reference

1. Lavoine, N., Colas, C. & Muleris, M. Constitutional mismatch repair deficiency syndrome: clinical description in a French cohort. *J Med Genet* 2015;52:770–778.
2. Wimmer, K., Kratz, C. P. & Vasen, H. F. A. Diagnostic criteria for constitutional mismatch repair deficiency syndrome: suggestions of the European consortium 'Care for CMMRD' (C4CMMRD). *J Med Genet* 2014;51:355–365.
3. Durno, C. A., Sherman, P. M. & Aronson, M. Phenotypic and genotypic characterisation of biallelic mismatch repair deficiency (BMMR-D) syndrome. *European Journal of Cancer* 2015; 51: 977-983.